



8TH - 10TH NOVEMBER, 2024 | GRAND HYATT MUMBAI

Registration number: 273

Title of the presentation:

MIRACULOUS HEALING WITH MICROWAVE ABLATION:
Role of microwave ablation in a rare case of inoperable lymphangioma of the mediastinum

AUTHORS AND INSTITUTE:

Dr. Akanksha Giri , Junior Resident(1st Author and presenter)

Dr. Roy Santhosham, Professor

Dr. Kiran Gopinathan, Assistant Professor

Dr. Bhawna Dev, Professor

Dept. of Radio-Diagnosis

Sri Ramachandra Institute of Higher Education and Research

Porur, Chennai

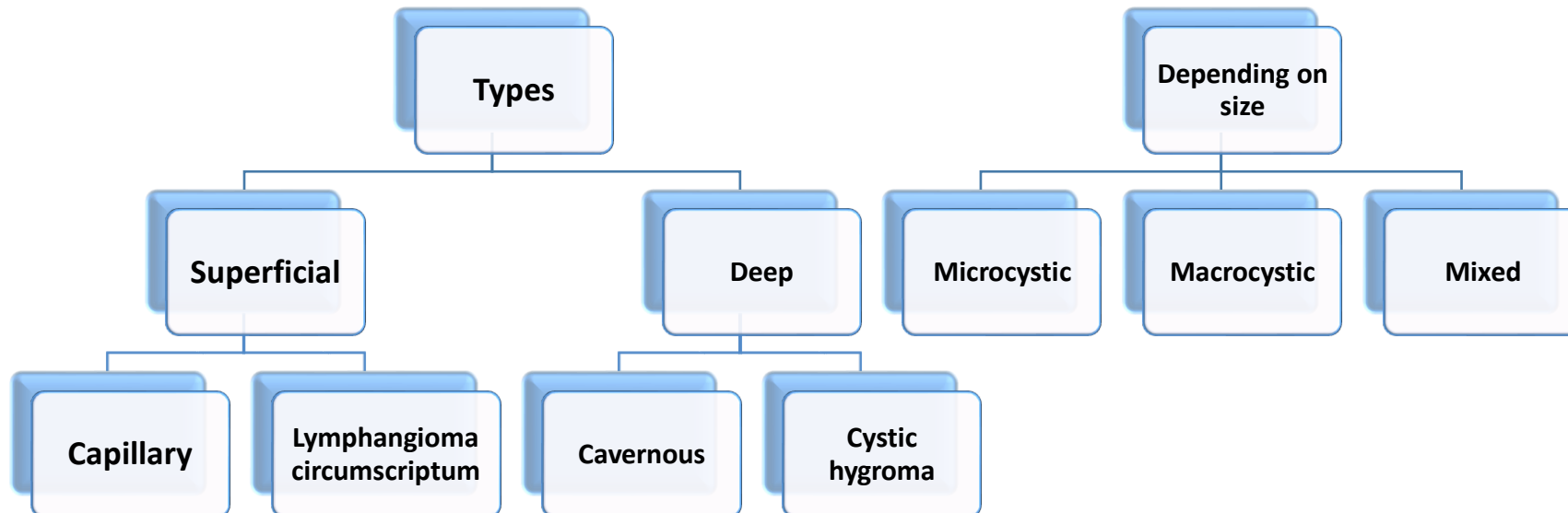
INTRODUCTION:



Lymphangiomas are benign vascular tumors consisting of fluid filled spaces(cysts) that occur due to abnormal lymphatic hyperplasia

Almost always they present at birth and identified by 2 yrs of life.

Adult presentations are rare with mediastinal location being one of the rarest



AIMS/ OBJECTIVES:



1

To elicit the role of Microwave Ablation in the treatment of an inoperable case of Lymphangioma with vascular connections

2

To emphasize the importance of combination therapy in complicated cases of lymphangioma

Lesion encased arch of aorta, left subclavian and left pulmonary artery

INOPERABLE

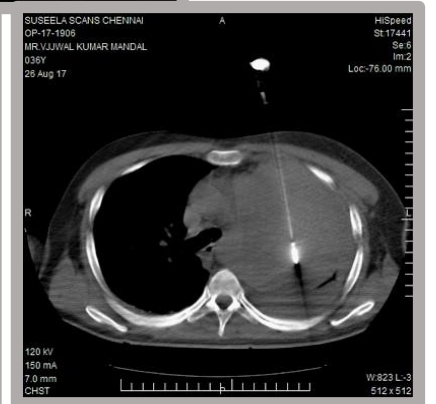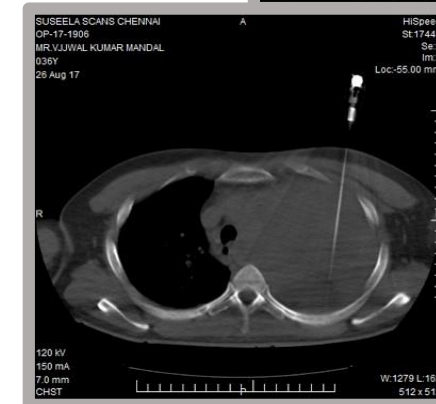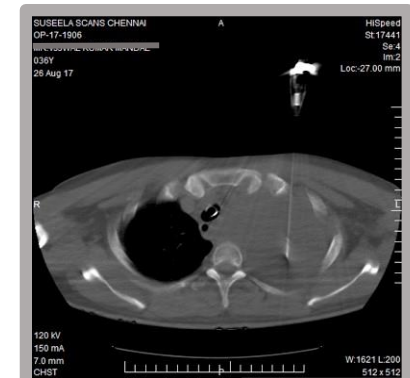Lesion showed vascular connection with pulmonary artery

SCLEROTHERAPY CAN'T BE DONE

Palliative T/T- 3-D CRT(TD-20 Gy)-
200 cGy/#for 10 days

NO IMPROVEMENT

CT-Guided Microwave Ablation
from 3 sites of entry with
6 overlapping ablation



AND TREATMENT

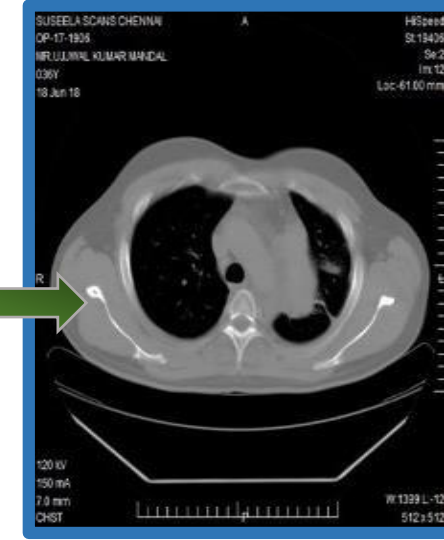
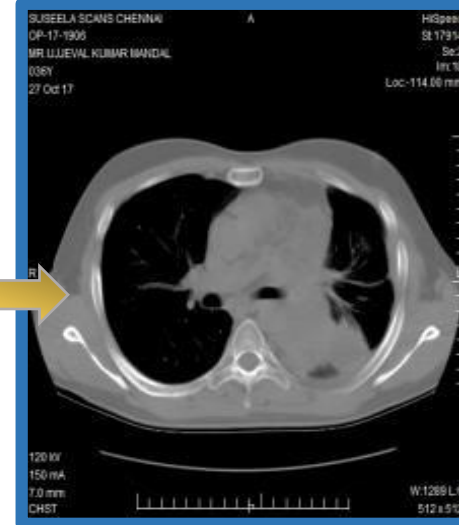
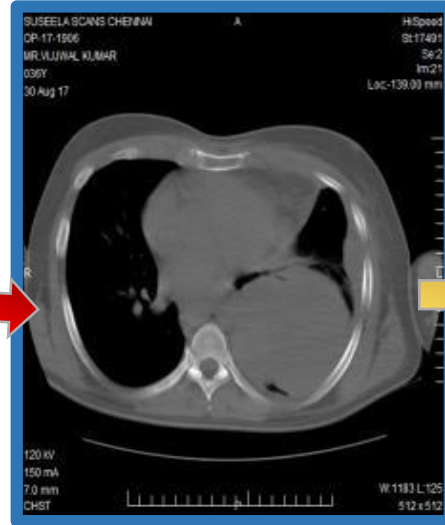
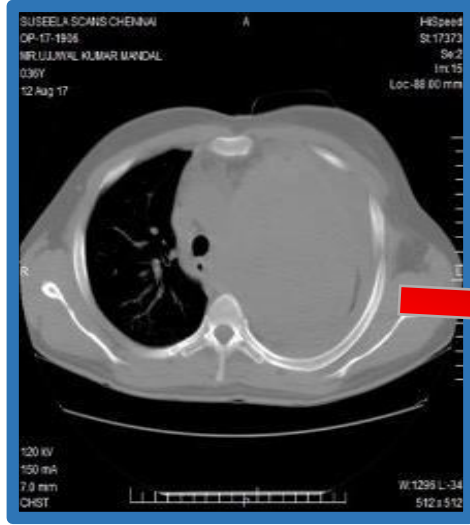
RESULTS:

PRE-PROCEDURAL

2 MONTHS

4 MONTHS

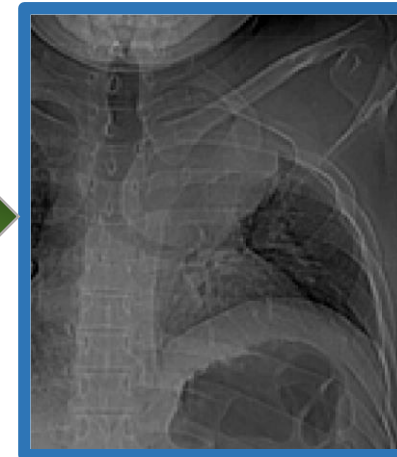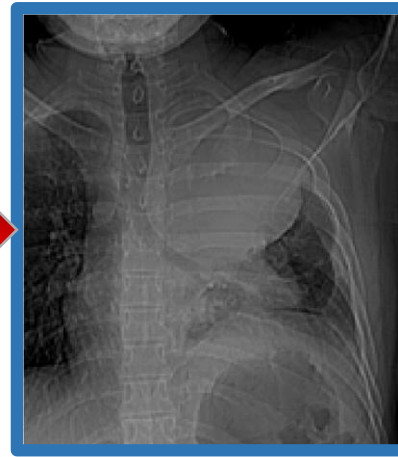
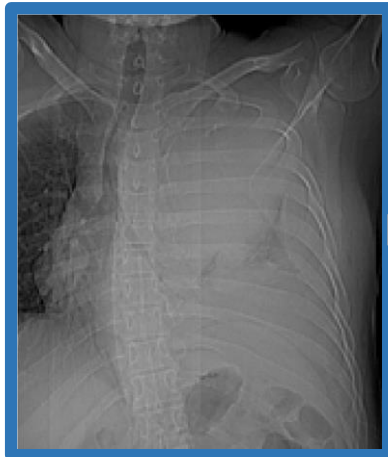10 MONTHS



PRE-PROCEDURAL

2 MONTHS

4 MONTHS



Significant improvement immediately with near complete resolution over 10 months interval

CONCLUSION:

Lymphangiomas are benign cystic tumors that can occur anywhere in body

Surgery is the mainstay of treatment

Microwave ablation can be useful in inoperable and recurrent cases

Combination therapy is an exciting and promising way forward

MICROWAVE ABLATION

RADIOFREQUENCY
ABLATION

SCLEROTHERAPY

MINIMALLY
INVASIVE
LOCAL
THERAPIES



SURGERY



FAVOURABLE
OUTCOME

REFERENCES:



1

- FOKKEMA JP, PAUL MA, VROUENRAETS BC. MEDIASTINAL LYMPHANGIOMA IN AN ADULT. *ANN R COLL SURG ENGL*. 2014;96(5):E24-E25. DOI:10.1308/003588414X13946184901209

2

- DENG D, NIU M, YANG J, DENG L. SIMPLE LYMPHANGIOMA OF THE SCROTUM: A CASE REPORT. *CLIN COSMET INVESTIG DERMATOL*. 2022;15:2017-2020. PUBLISHED 2022 SEP 22. DOI:10.2147/CCID.S375428

3

- SACHDEVA S. LYMPHANGIOMA CIRCUMSCRIPTUM TREATED WITH RADIOFREQUENCY ABLATION. *INDIAN J DERMATOL*. 2011;56(1):77-78. DOI:10.4103/0019-5154.77558